

Surgical Approaches to Myopia Treatment

Surgeons discuss their preferred approaches to treating myopia.

BY ARTHUR CHENG, MBBS, MRCS(Ed), FCOPTH, FRCOPHTH(UK); YONG MING POR, MBBS, FRCS(Ed), FRCS(GlasG), MMED(OPHTH), MRCOPHTH; AND JERRY TAN, MBBS, FRCS(Ed), FRCOPHTH, FAMS

ARTHUR CHENG, MBBS, MRCS(Ed), FCOPTH, FRCOPHTH(UK)

Myopia, the most common type of refractive error, accounts for more than 99.9% of refractive surgical corrections in my practice. Myopic correction can be achieved by changing the power of a part or parts of the existing refractive structure (ie, the cornea and lens) or by inserting an extra refractive medium such as a phakic IOL.

MYOPIC LASER CORRECTION

The most popular type of laser correction for myopia is LASIK. Myopic laser correction is achieved by central corneal ablation, which reduces the refractive power of the anterior corneal surface. Myopic LASIK has been shown to be effective in correcting low to moderate myopia.^{1,2} LASIK correction of high myopia has been fraught with quality issues until recently. Factors that have enhanced outcomes include increasing the effective optical zone, decreasing the quantity of tissue ablated, and reducing higher-order aberrations (HOAs), especially spherical aberration.

Before myopic laser correction, the cornea is prolate in shape, meaning that corneal power is stronger in the center than the periphery. A prolate cornea reduces spherical aberration. In myopic correction, the central cornea is ablated, resulting in a flatter anterior corneal surface. Previous-generation lasers resulted in an oblate cornea after myopic correction due to several factors. First, there is less laser energy power when the laser strikes the peripheral area, even though it is still within the optical zone. This is partly because this area is slightly out

of focus relative to the center of the cornea and partly because of the increase in the angle of incidence and the ovalization and consequent enlargement of the laser spot. Part of the laser energy is also reflected. As a result, the actual power delivered to the periphery of the cornea is lower than the intended power, causing underablation (Figure 1).

The end result is a cornea flatter in the center and less flat in the periphery of the optical zone. In other words, the resultant cornea is oblate and has a smaller effective optical zone. This is the reason for the nighttime myopia experienced by many highly myopic patients after LASIK correction. As the pupil gets larger at night, more light passes through the periphery of the optical zone and, because this area is steeper, more light is focused anterior to the retina. This is also part of the reason why patients experience glare and halos at nighttime.

In order to solve this problem, wavefront-optimized ablation profiles have been developed.³ Optimized ablation

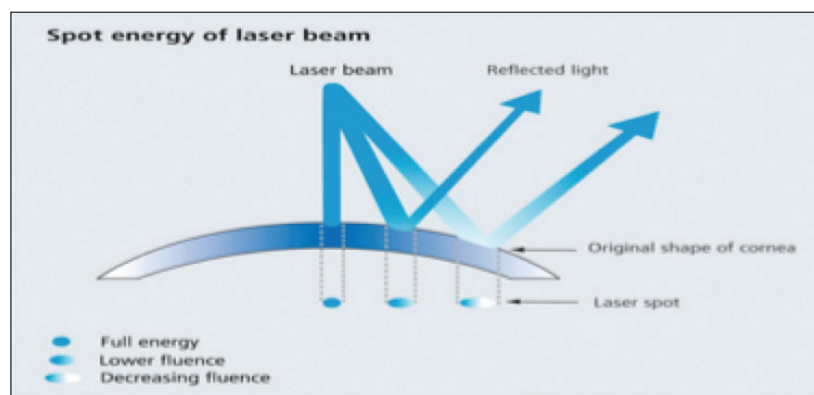


Figure 1. Due to the angle of incidence, the light of the laser beam is ovalized increasingly toward the periphery and becomes partially reflected. This results in less fluence and therefore suboptimal ablation.

Courtesy of Arthur Cheng, MD

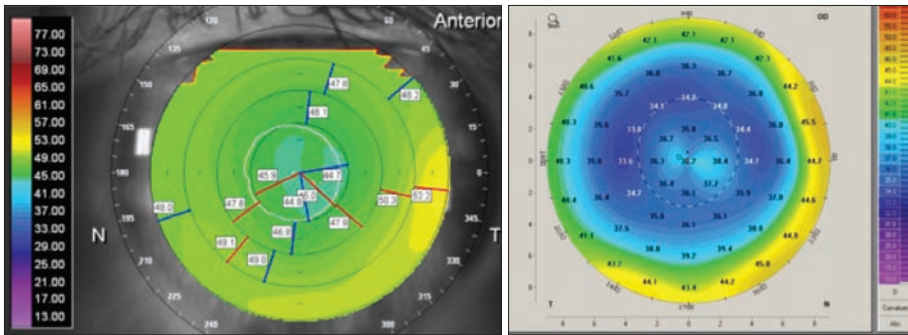


Figure 2. (A) A patient with -2.00 D correction with a 6.5-mm optical zone (OZ) using the Planoscan program Bausch + Lomb platform. The keratometry (K) values in the central cornea (first black ring, representing the central 3-mm zone) are lower than those in the area between the first and second black ring (denoting the 3- to 5-mm zone), which, in turn are lower than those in the 5- to 7-mm zone. (B) A patient with -10.00 D correction and a 6-mm OZ using the Wavelight Allegretto wavefront-optimized program. Note the higher K value in the center compared with the periphery within the OZ.

CLINICAL DATA

I evaluated 280 eyes of 140 patients with preoperative myopia up to -10.00 D who underwent myopic LASIK. All treatments were performed with a wavefront-optimized ablation profile using the Wavelight Allegretto platform (Alcon Laboratories, Inc.) with a 6.5-mm optical zone. At 6 months' follow-up, more than 97% of eyes achieved 20/25 UCVA or better, and more than 71% achieved 20/16 UCVA or better (Figure 3). There was no change in corneal spherical aberration from preoperative to postoperative in the 4-mm, 5-mm, and 6-mm zones. The predictability slope for refraction was 1.02, and the intercept value was 0.00 D.

WAVEFRONT-GUIDED VERSUS WAVEFRONT-OPTIMIZED TREATMENT

There is a fundamental difference between wavefront-guided and wavefront-optimized treatment algorithms. Wavefront-guided treatment aims to correct the HOAs that exist before LASIK; it does not attempt to correct or compensate for aberrations generated during the procedure.

Wavefront-optimized treatment does not consider the preoperative HOAs but rather compensates for those generated by the procedure.

Below a certain level (approximately 0.3 μm root mean square HOA for a 6-mm treatment zone), there is practically no difference between the two techniques.⁴ However, with larger HOAs, in the range of 0.6 or 0.7 μm for a 6-mm treatment zone, outcomes are better after wavefront-guided treatment (Figure 4). Therefore, wavefront-guided treatment is preferable when significant amounts of HOAs are present, but wavefront-optimized treatments are the better choice

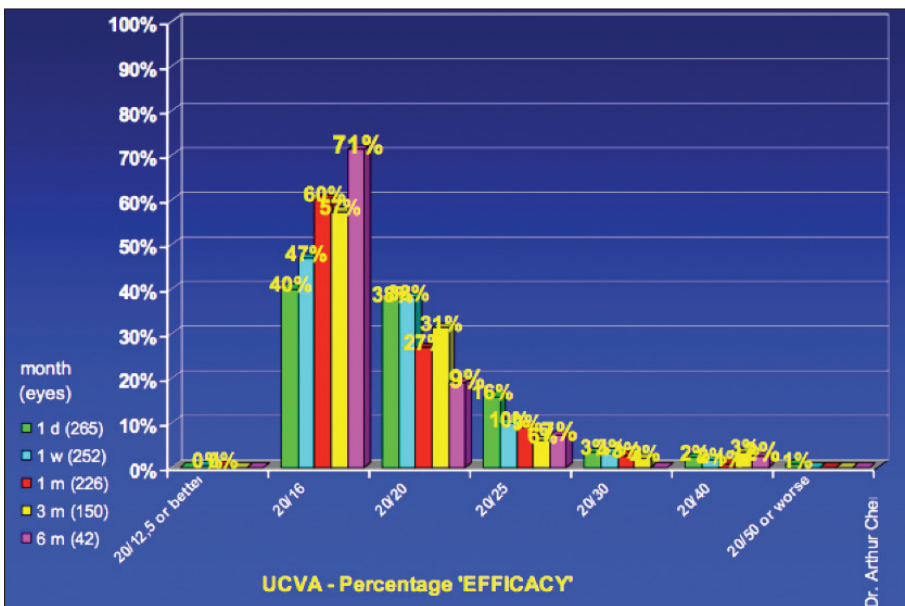


Figure 3. At 6 months' follow-up, more than 97% of eyes that underwent myopic LASIK achieved 20/25 UCVA or better, and more than 71% achieved 20/16 or better.

profiles aim to maintain the cornea's pre-LASIK spherical aberration; this is achieved by compensating for the peripheral effects mentioned above. Figure 2A shows a patient with 2.00 D of myopia who underwent conventional LASIK in 1997, and Figure 2B shows the corneal topography of a patient who underwent wavefront-optimized LASIK for 10.00 D of myopia in 2010. It is easy to compare the oblate cornea resulting from a low conventional myopic correction and the prolate cornea with high correction achieved with a wavefront-optimized ablation profile.

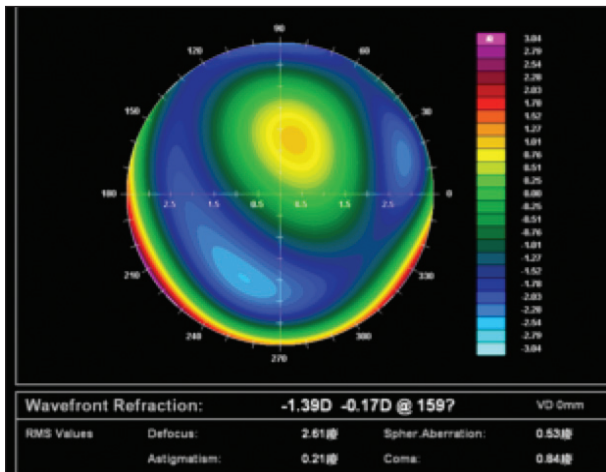


Figure 4. A patient with wavefront-guided treatment with postoperative high spherical aberration of 0.53 μm .

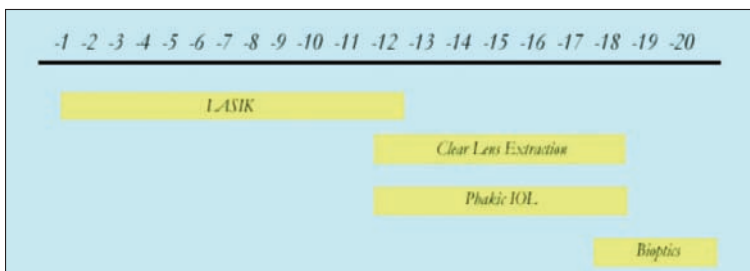


Figure 5. Different ranges of myopia require different surgical approaches. Bioptics can be considered for patients with extreme myopia (more than -16.00 D).

for the majority of the population, who have less severe visual disturbances. When LASIK is used to treat a highly myopic patient, the HOAs generated during the procedure are far greater than the preexisting aberrations, and therefore a wavefront-optimized approach would be a better choice.

LIMITATIONS OF CORNEAL THICKNESS

Corneal thickness is another limiting factor in laser myopic correction. The current generation of lasers using sub- 1-mm spot sizes has already reduced the amount of tissue ablated per diopter of treatment. However, in patients with thin corneas, or in those with large pupils for whom large optical zones are required, corneal thickness is still a limiting issue. The ability of femtosecond laser technology to create consistently thin flaps (sub-Bowman keratomileusis) allows more tissue to be available for treatment. This technique yields consistent outcomes with low complication rates.⁵

In patients with very thin corneas or in whom high correction is needed, surface ablation provides an alternative for myopic correction. Surface ablation outcomes comparable with those of LASIK have been reported.⁶ However,

mitomycin C is required to minimize postoperative haze. In my practice, I apply 0.02% mitomycin C for 1 minute for all surface myopic corrections greater than -3.00 D . Our internal data show no difference between LASIK and surface ablation outcomes at 3-month follow-up in terms of visual acuity or regression. However, visual rehabilitation takes longer in patients who undergo surface ablation.

PHAKIC IOLs

In patients with extremely thin corneas or in those with very high myopia, phakic IOLs may be the only surgical treatment option. Good visual outcomes have been reported with phakic IOLs. Pérez-Vives et al⁷ compared contrast sensitivity, modulation transfer function, and point spread function in patients undergoing LASIK and phakic IOL implantation (Visian ICL, STAAR Surgical). The investigators found that both ICL implantation and LASIK provided good optical and visual quality. The ICL, however, provided better outcomes, especially for eyes with large refractive errors or pupil sizes. These outcomes can be attributed to the greater induction of HOAs by LASIK than by ICL implantation. In patients with extreme myopia (more than -16.00 D), a bioptics procedure can be considered, in which the majority of the refractive error is corrected by IOL implantation and the rest by corneal laser ablation (Figure 5).

CONCLUSION

Both corneal and lens-based approaches are effective in reducing patients' spectacle dependence, with equally good refractive outcomes and minimal side effects possible in well-selected patients.

Arthur Cheng, MBBS, MRCS(Ed), FCOphth, FRCOphth(UK), is a Consultant Ophthalmologist at Hong Kong Sanatorium Hospital and an Honorary Clinical Associate Professor at The Chinese University of Hong Kong and The University of Hong Kong. Dr. Cheng has received travel grants from Alcon Laboratories, Inc. He may be reached at e-mail: drarthurcheng@gmail.com.

- Pallikaris IG, Siganos DS. Excimer laser in situ keratomileusis and photorefractive keratectomy for correction of high myopia. *J Refract Corneal Surg.* 1994;10(5):498-510.
- Salah T, Waring GO 3rd, el-Maghraby A, Moadel K, Grimm SB. Excimer laser in-situ keratomileusis (LASIK) under a corneal flap for myopia of 2 to 20 D. *Trans Am Ophthalmol Soc.* 1995;93:163-183; discussion 184-190.
- Mrochen M, Donitzky C, Wüllner C, Löffler J. Wavefront-optimized ablation profiles: theoretical background. *J Cataract Refract Surg.* 2004;30:775-785.
- Stonecipher KG, Kezirian GM. Wavefront-optimized versus wavefront-guided LASIK for myopic astigmatism with the Allegretto Wave: three-month results of a prospective FDA trial. *J Refract Surg.* 2008;24(4):S424-430.
- Slade SG. Thin-flap laser-assisted in situ keratomileusis. *Curr Opin Ophthalmol.* 2008;19(4):325-329.
- Djodeyre MR, Ortega-Usobiaga J, Beltran J, Baviera J. Long-term comparison of laser in situ keratomileusis versus laser surface ablation in corneas thinner than 470 μm . *J Cataract Refract Surg.* 2012;38(6):1034-1042.
- Pérez-Vives C, Dominguez-Vicent A, García-Lázaro S, Ferrer-Blasco T, Montés-Micó R. Optical and visual quality comparison of implantable Collamer lens and laser in situ keratomileusis for myopia using an adaptive optical visual simulator [published online ahead of print July 30, 2012]. *Eur J Ophthalmol.* doi:10.5301/ejo.5000188.

YONG MING POR, MBBS, FRCS(Ed), FRCS(GLASG), MMED(OPHTH), MRCOPHTH; AND JERRY TAN, MBBS, FRCS(Ed), FRCOPHTH, FAMS

Although attempts to treat myopia surgically go back more than a half century, it was with the advent of radial keratotomy and then excimer laser corneal surgery that refractive surgery found wide acceptance. Radial keratotomy has since fallen by the wayside due to refractive instability and long-term hyperopic drift. Excimer laser corneal reshaping began with surface ablation (PRK) and proceeded to intrastromal ablation in the form of LASIK, and both approaches are still in use today.

Surface ablation techniques now include LASEK, epi-LASIK, and traditional PRK. Although the original aim of both LASEK and epi-LASIK was to replace the epithelial sheet and thereby improve patient comfort and reduce the risk of haze, recent studies have shown no difference in haze or long-term visual outcomes whether the epithelial sheet was replaced or discarded.^{1,2} Paradoxically, early postoperative pain was less when the epithelial flap was removed in these two studies. Besides this, corneal epithelial healing was also faster when the epithelial flap was removed.¹⁻³ In our practice, we usually perform flap-off LASEK (alcohol-assisted PRK) for patients who require surface ablation.

Surface ablation techniques still have a role in patients who are at higher risk for blunt eye trauma or whose corneas are too thin to allow conventional LASIK. In general, we consider the adjunctive use of mitomycin C to be a requirement in all cases of surface ablation to reduce the risk of postoperative corneal haze and scarring. Additionally, we avoid performing surface ablations for corrections greater than -7.00 D, as it is our impression that the risk of haze remains substantial even with the use of mitomycin C, especially because of the tropical sunshine in Singapore.

At this time, LASIK remains the gold standard for surgical correction of myopia. As corneal stromal ablation in LASIK is performed under an intact Bowman layer, there is minimal risk of scarring and a reduced risk of myopic regression. Recovery of both vision and comfort is much faster than with surface ablation techniques. LASIK has long been used to address the lower-order aberrations of sphere and cylinder. More recently, attempts have been made to address HOAs with LASIK. The two main ways by which this can be achieved are with ocular-wavefront-guided ablations or with ablations guided by corneal topography or corneal wavefront. Ocular-wavefront-guided ablations utilize an aberrometer to measure the wavefront for the eye's whole optical system, while topography-guided ablations use corneal topography

TAKE-HOME MESSAGE

- Myopic correction can be achieved by changing the power of a part or parts of the existing refractive structure (ie, the cornea and lens) or by inserting an extra refractive medium such as a phakic IOL.
- Both corneal and lens-based approaches are effective in reducing spectacle independence in well-selected patients.
- LASIK is currently the gold standard for achieving surgical myopic correction.

and corneal wavefront data, which may be derived from Placido disc or Scheimpflug images.

In our opinion, data based on corneal topography are preferable. Whole-eye wavefronts are variable and depend on factors such as the state of accommodation of the eye and the size of the pupil. The best Hartmann-Shack aberrometers measure about 1,000 points, while a corneal topographer typically measures more than 20,000 data points per cornea, allowing more precise customization. Topography-guided ablations have recently been shown to induce fewer aberrations compared with wavefront-optimized algorithms.⁴ In fact, in some of our patients, topography-guided ablations not only induce fewer aberrations, but they also successfully reduce pre-existing corneal aberrations (Figure 6).

UPPER LIMITS OF TREATMENT

The fundamental constraint with any form of laser vision correction is the need to maintain sufficient residual corneal stroma to avoid weakness and corneal ectasia, while maximizing the optical zone to minimize the effect of aberrations in scotopic conditions. Bühren et al⁵ showed that an optical zone just 9% smaller than the pupil diameter resulted in the induction of 50% more HOAs than an optical zone that was equal to the pupil diameter. In practice, we aim to always provide an optical zone that is larger than the patient's scotopic pupillary diameter. The minimum optical zone we employ is 6 mm; in most cases, it is greater than 6.5 mm.

Although it is likely that the minimum residual stromal thickness to avoid ectasia varies from patient to patient, we currently adhere to the conventional limit of 250 μm . For cases in which we anticipate a residual stromal thickness of 250 to 300 μm , we perform accelerated corneal collagen crosslinking (CXL) following the protocol of Avedro (LASIK Xtra). Regardless of the availability of a CXL treatment, we will not perform excimer laser surgery on any patient who manifests signs of forme fruste keratoconus, such as skewed bow-tie astigmatism or markedly asymmetrical bow-tie astigmatism.

Courtesy of Yong Ming Por, MBBS, FRCS(Glasg), FRCS(Ed), FRCS(Glasg), MMed(Ophth), MRCOphth, and Jerry Tan, MBBS, FRCS(Ed), FRCOphth, FAMS

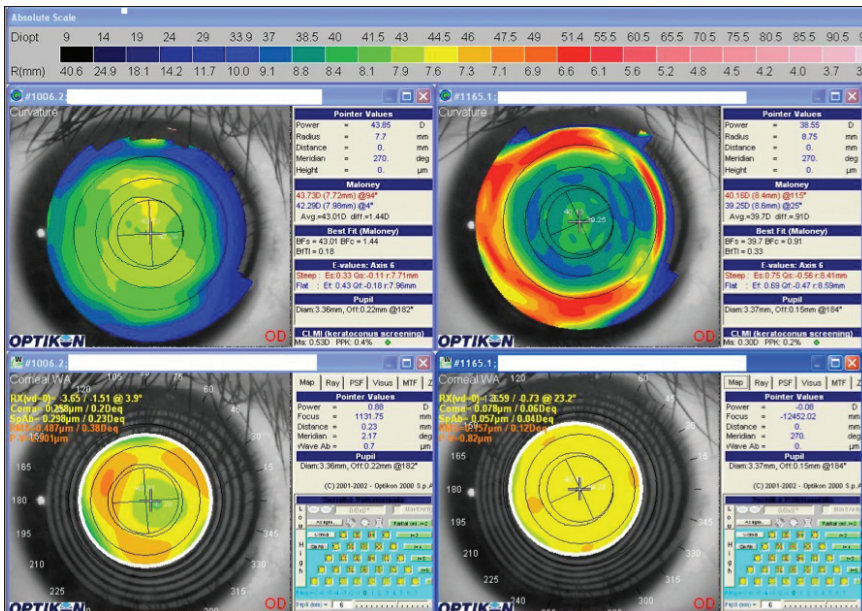


Figure 6. Topography-guided ablations have been shown to induce fewer aberrations compared with wavefront-optimized algorithms. In some patients, topography-guided ablations also successfully reduce preexisting corneal aberrations.

Considering the constraints of minimum residual stromal thickness and an optical zone greater than the scotopic pupil diameter, a general upper limit of myopia treatment for an average corneal thickness of 550 µm is about -12.00 D spherical equivalent.

BEYOND THE UPPER LIMIT

Beyond the limits of excimer laser surgery, available options are lens-based surgery alone or in combination with excimer laser surgery (bioptics). Lens-based surgical options include implantation of phakic IOLs and, in some instances, refractive lens exchange.

Currently available phakic IOLs include anterior chamber angle-supported lenses such as the Cachet (Alcon Laboratories, Inc.) and iris-supported lenses such as the Verisyse (Abbott Medical Optics Inc.). Our lens of choice is the Visian ICL (STAAR Surgical), which is implanted behind the iris in the posterior chamber and may pose a lower risk of long-term endothelial loss. A recent review found a mild increase in corneal endothelial cell loss within the first 1 to 2 years after surgery with the ICL, followed by stability or slower progression after that time.⁶ Additionally, the Toric ICL offers the ability to correct cylindrical refractive errors of up to 6.00 D. Recent refinements in the ICL design include the v4c lens, which has a small central aperture that facilitates aqueous flow. This obviates the need for peripheral iridotomies and may minimize the risk for iridotomy-related lens opacities.

Refractive lens exchange (otherwise known as *clear lens extraction*) is another method to correct very high myopic refractive errors. We consider this procedure to be contraindicated in presbyopes and generally avoid performing it in presbyopic high myopes. In one study, as many as 20% of patients were found to develop a posterior vitreous detachment within 1 week after cataract surgery,⁷ and in highly myopic patients this could be associated with a higher risk of retinal detachment.

CONCLUSION

LASIK is currently the gold standard for achieving surgical myopic correction. As with any form of laser vision correction, it is necessary to maintain sufficient residual corneal stroma to avoid weakness and corneal ectasia, while maximizing the optical zone to minimize the effect of aberrations in scotopic conditions. Alternative approaches for the correction of myopia include lens-based surgery alone or in combination with excimer laser surgery. ■

Alternative approaches for the correction of myopia include lens-based surgery alone or in combination with excimer laser surgery. ■

Yong Ming Por, MBBS, FRCS(Ed), FRCS(Glasg), MMed(Ophth), MRCOphth, is a Consultant Eye Surgeon at Jerry Tan Eye Surgery Pte Ltd., Singapore. Dr. Por states that he has no financial interest in the products or companies mentioned. He may be reached at e-mail: drpor@jerrytan.com.

Jerry Tan, MBBS, FRCS(Ed), FRCOphth, FAMS is the owner and Medical Director of Jerry Tan Eye Surgery Pte Ltd., Singapore. Dr. Tan states that he is a consultant for Schwind eye-tech-solutions. He may be reached at tel: + 65 6738 8122; e-mail: info@jerrytan.com.



- Liu XQ, Xu L, Yi CJ. Flap removal or flap preservation during LASEK surgery. *Cell Biochem Biophys*. 2010;57:45-48.
- Na KS, Lee KM, Park SH, Lee HS, Joo CK. Effect of flap removal in myopic epi-LASIK surgery on visual rehabilitation and postoperative pain: a prospective intraindividual study. *Ophthalmologica*. 2010;224:325-331.
- Kalyvianaki MI, Kymionis GD, Kounis GA, Panagopoulou SI, Grentzelos MA, Pallikaris IG. Comparison of epi-LASIK and off-flap epi-LASIK for the treatment of low and moderate myopia. *Ophthalmology*. 2008;115(12):2174-2180.
- El Awady HE, Ghanem AA, Saleh SM. Wavefront-optimized ablation versus topography-guided customized ablation in myopic LASIK: comparative study of higher order aberrations. *Ophthalmic Surg Lasers Imaging*. 2011;42(4):314-320.
- Bühren J, Kühne C, Kohnen T. Influence of pupil and optical zone diameter on higher-order aberrations after wavefront-guided myopic LASIK. *J Cataract Refract Surg*. 2005;31(12):2272-2280.
- Fernandes P, González-Mejome JM, Madrid-Costa D, Ferrer-Blasco T, Jorge J, Montés-Micó R. Implantable collamer posterior chamber intraocular lenses: a review of potential complications. *J Refract Surg*. 2011;27(10):765-776.
- Mirshahi A, Hoehn F, Lorenz K, Hattenbach LO. Incidence of posterior vitreous detachment cataract surgery. *J Cataract Refract Surg*. 2009;35(6):987-991.